

Broader Curve Criteria for Selective Thoracic Fusion

Kao-Wha Chang, MD, PhD,*† Xiangyang Leng, MD,† Wenhai Zhao, MD,† Yin-Yu Chen, MD,*
Tsung-Chen Chen, MD,* and Ku-I Chang, MD*

Study Design. Retrospective radiographic review.

Objective. To evaluate the outcome of selective thoracic fusion [AQ1] (STF) by using cantilever bending technique (CBT) and the direct vertebral rotation (DVR) technique for major thoracic-compensatory lumbar (MTCL) curves selected by new curve criteria, which are broader than Lenke curve criteria for STF.

Summary of Background Data. Surgical treatment of MTCL curves aims to maximize the number of MTCL curves that can be treated with STF and optimize instrumented thoracic and spontaneous lumbar correction. Comparing current guidelines for STF shows that the surgical technique utilized for STF may affect the curve criteria for MTCL curves for successful STF and thoracic and lumbar correction.

Methods. Seventy-eight consecutive idiopathic scoliosis patients with major thoracic-compensatory “C” modifier lumbar curves who met the following three criteria: (1) main thoracic curve (MT) to compensatory lumbar curve (CL) ratios of Cobb magnitude and apical vertebral translation (AVT) greater than one; (2) MT/CL ratio of flexibility less than one; (3) Cobb magnitude of lumbar curve less than 35° on side bending, were treated with STF by using CBT and DVR. Radiographs were analyzed before surgery, immediately after surgery, and at the most recent follow-up (range, 2–5 years).

Results. All 78 MTCL curves were successfully treated with STF by using CBT and DVR. A mean 61% thoracic correction was matched by 55% lumbar correction at the most recent follow-up. Spontaneous correction of lumbar AVT occurred in all patients. Global coronal imbalance was common before surgery (mean, 14 mm) and remained so after surgery (mean, 12 mm). There were 49 MTCL curves that did not meet Lenke curve criteria for STF. All were successfully treated with STF by using CBT and DVR. Among these 49 MTCL curves, there were 14 Lenke 1C and 18 Lenke 2C curves with one or two, or all of MT/CL ratios of Cobb magnitude, AVT, and apical vertebral rotation of 1.2 or less, and 6 Lenke 3C and

11 Lenke 4C curves with the Cobb magnitude of residual lumbar curve on side bending between 25° and 35°.

Conclusion. CBT and DVR can broaden the current curve criteria of MTCL curves for STF to have more MTCL curves treatable with STF and optimize instrumented thoracic and spontaneous lumbar correction. A more effective surgical technique can not only improve instrumented thoracic and spontaneous lumbar correction but also can broaden the MTCL curve criteria for STF to have more MTCL curves treatable with STF.

Key words: cantilever bending technique, direct vertebral rotation, major thoracic-compensatory lumbar curve, selective thoracic fusion.

Spine 2011;XX:1–7

Despite the continual evolution in the surgical treatment of idiopathic scoliosis, the goals of surgery have remained the same. It is desirable to obtain solid fusion while providing safe and optimal coronal correction, sagittal alignment, and axial derotation. Fusing the smallest number of spinal segments possible while achieving these goals is also desirable to maximize motion segments both above and below the fused spinal segments. This philosophy holds true when treating major thoracic-compensatory lumbar (MTCL) curves, where the goal is to perform selective thoracic fusion (STF), while leaving the lumbar spine unfused, in those cases amenable to this technique. Ideally, after STF, the unfused lumbar curve will spontaneously accommodate to the corrected position of the thoracic curve, achieving the ultimate goal of a balanced spine, with the fusion mass centered over the pelvis and a maximum number of unfused lumbar spinal segments remaining.

Currently, there are three guidelines for STF. These guidelines were proposed by King *et al*,¹ Lenke *et al*,² and Peking Union Medical College (PUMC)³ (Table 1). By using the curve criteria to select appropriate MTCL curves for STF, the appended surgical technique can guarantee successful STF. Comparing these guidelines, we found that the stricter the curve criteria, the less is the restriction on the surgical technique and the better is the correction. PUMC’s curve criteria are the strictest among the three; the lumbar curve must be less than 45°, and its flexibility must be more than 70%; however, the appended surgical technique is without any restriction and can utilize modern instrumentation to provide derotation,

From the *Taiwan Spine Center, Jen-Ai Hospital, Taichung, Taiwan, Republic of China; and †Affiliated Hospital of Changchun University of Chinese medicine, Changchun, Jilin, People Republic of China.

Acknowledgment: April 30, 2010. First revision date: August 11, 2010. Accepted date: February 11, 2011.

Address correspondence and reprint requests to Kao-Wha Chang, MD, PhD, Taiwan Spine Center, Jen-Ai Hospital, Taiwan, No. 483 Dong Rong Rd, Tali, Taichung, Taiwan, Republic of China; E-mail: admin_c@taiwanspinecenter.com.tw

DOI: 10.1097/BRS.0b013e318215fa73

Spine

www.spinejournal.com

1

Copyright © 2011 Lippincott Williams & Wilkins. Unauthorized reproduction of this article is prohibited.

TABLE 1. Current Guidelines for Major Thoracic-Compensatory Lumbar Curves for Selective Thoracic Fusion

Guideline	Curve Criteria	Surgical Technique	Correction
King <i>et al</i> ¹	T curve \geq L curve	Distraction	T 40.6% ¹
	Positive flexibility index	Harrington distraction instrumentation	L 34.8%
Lenke <i>et al</i> ²	T curve $>$ L curve	No derotation	T 36% ⁵
	Positive flexibility index	Not overcorrection	L 33%
	L curve $<$ 25° on side bending	Modern segmental spinal instrumentation	
	TL kyphosis $<$ 20°		
	T/L ratio of Cobb, AVR, AVT $>$ 1.2		
PUMC ³	L curve \square T curve \leq 10°	Derotation	T 60% ⁴
	Positive flexibility index	Distraction	L 64%
	No TL kyphosis	Translation	
	L curve \leq 45°	Modern segmental spinal instrumentation	
	Lumbar AVR $<$ 2 Grade II (N-M method)		
	L flexibility \geq 70%		

AVR indicates apical vertebral rotation; AVT, apical vertebral translation; L, lumbar; N-M, Nash-Moe; PUMC, Peking Union Medical College; T, thoracic.

distraction, and translation, and it results in instrumented thoracic correction of 60% and spontaneous lumbar correction of 64%.⁴ Curve criteria of King *et al*¹ are the broadest among the three; however, only if the thoracic curve is larger than the lumbar curve and the lumbar curve is more flexible than the thoracic curve can the MTCL curve be treated with STF. Moreover, the appended surgical technique is severely restricted so that only distraction by Harrington instrumentation can be used, and this results in thoracic correction of 41% and lumbar correction of 35%.¹ Lenke's curve criteria are not as strict as PUMC's criteria. Lumbar curves more than 45° can still be treated with STF if thoracic to lumbar ratio criteria of Cobb magnitude, apical vertebral translation (AVT), and apical vertebral rotation (AVR), all are 1.2 or greater. However, restriction of surgical technique, including avoidance of overcorrection and derotation, are required, and the resulting correction is inferior to that in the PUMC series (thoracic correction: 36% and lumbar correction: 33%).⁵

[AQ2] Curve criteria are related to the number of MTCL curves appropriate for STF. The stricter the curve criteria, the fewer are the MTCL curves that can be treated with STF. Surgical technique is related to the correction of MTCL curves. The more the limitation of the surgical technique, the poorer will be the correction. So if the curve criteria of King *et al* or Lenke *et al* are followed to have more MTCL curves treated by STF, we must accept correction of about 40%. If we want to increase correction to 60%, we must follow PUMC curve criteria for selecting patients, and fewer MTCL curves can be treated by STF. The quantity of MTCL curves treatable with STF and the correction of MTCL curves treated with STF are thus conflicting goals. This is the current status of MTCL curves treated with STF and certainly is not a status spine surgeons would be satisfied with. Spine surgeons want

the quantity of MTCL curves treatable with STF to be as high as possible and the correction of MTCL curves treated with STF to be as good as possible.

We believe that a more effective surgical technique can not only improve instrumented thoracic and spontaneous lumbar correction but also can broaden the MTCL curve criteria for STF to have more MTCL curves able to be treated with STF. We combined the cantilever bending technique (CBT) and direct vertebra rotation (DVR) as a technique for STF to treat MTCL curves⁶ and demonstrated that the technique can control the corrective forces for STF and maximize instrumented thoracic (83%) and spontaneous lumbar (81%) correction while maintaining the quantity of MTCL curves selected by the curve criteria of Lenke *et al*.⁶ The objective of this study was to demonstrate that this technique can add more MTCL curves for STF than the quantity of MTCL curves for STF following Lenke curve criteria while optimizing correction.

MATERIALS AND METHODS

Seventy-eight consecutive MTCL curves, in which both the thoracic and lumbar curves crossed the midline (all C lumbar modifier) and met the following three criteria: (1) main thoracic curve (MT) of compensatory lumbar curve (CL) ratios of Cobb magnitude and AVT greater than one; (2) MT/CL ratio of flexibility less than one; and (3) the lumbar curve on side bending was less than 35°, were treated with STF by using CBT and DVR at a single institution between 2004 and 2007. Radiographic follow-up was a minimum of 2 years.

Radiographic Evaluation

Preoperative long-cassette standing upright anteroposterior (AP) and lateral radiographs, as well as right and left supine

best-effort side-bending coronal radiographs, were independently reviewed. Standing long-cassette AP and lateral radiographs from preoperative, immediate postoperative, and most recent follow-up were evaluated to determine changes in radiographic characteristics. Coronal and sagittal curves were measured according to the Cobb method. Junctional kyphosis between the MT and CT curve was noted. Curve types were classified according to classification system of Lenke *et al.*²

All MTCL curves had a definite C lumbar modifier before surgery. The *stable vertebra* was defined as being the most proximal lumbar or lower thoracic vertebra bisected (or nearly bisected) by the central sacral line, which is a line drawn through the center of the sacrum perpendicular to the iliac crests. If a disc was nearly bisected, then the next caudal vertebra was chosen as the stable vertebra. The stable vertebra was designated the distal level of instrumentation and fusion. [AQ3]

Curve flexibility was determined by measuring the proximal thoracic curve (PT), MT, and CL curve magnitudes on the preoperative standing AP, and lateral and supine right, and left best-effort side-bending radiographs. Flexibility and correction for the PT, MT, and CL curves were determined. Flexibility was calculated as follows: preoperative standing posterior-anterior Cobb angle—side-bending Cobb angle/preoperative standing posterior-anterior Cobb angle $\times 100\%$. Correction was calculated as follows: preoperative standing posterior-anterior Cobb angle—postoperative standing posterior-anterior Cobb angle/preoperative standing posterior-anterior Cobb angle $\times 100\%$.

Additional criteria measured from the AP radiograph were MT and CL AVT and AVR. AVT for the MT curve was measured relative to the coronal C7 plumb line. AVT for the CL curve was measured relative to the center sacral vertical line, which should bisect the cephalad aspect of the sacrum and be perpendicular to the true horizontal.² AVR for the MT and lumbar curves was assessed according to the system devised by Nash and Moe.⁷ Global coronal and sagittal balance were determined by measuring the horizontal distance from a vertical line extended from the center of the C7 vertebral body relative to the center sacral vertical line and posterior superior corner of S1. When averaging the translational measurement (coronal and sagittal balance), we used absolute values so that the positive and negative value did not cancel each other out. Measures of preoperative and postoperative balance were compared. Thoracolumbar kyphosis was noted if the Cobb angle between T12 and L1 was more than 10° on the sagittal plane. Each postoperative radiograph was assessed for the evidence of implant failure, loss of fixation, and nonunion. MTCL curves meeting or not meeting Lenke curve criteria for STF were recorded.

Statistical Analysis

Descriptive statistical analysis was performed for each dependent variable by comparing the preoperative radiographic data with that obtained at the various postoperative time points by using a mixed model analysis of variance. Specific comparisons of radiographic criteria were performed by analysis of covariance. Pairwise comparisons of the radiographic

data were performed by using the Fisher exact test. Statistical significance was set at $P < 0.05$.

Surgical Techniques

We used CBT and DVR to correct the thoracic curve. The surgical procedures have been described previously.⁶

RESULTS

Of the 78 patients, 70 were women and 8 were men. Their mean age was 18.1 years (range, 14.1–29.4 years). The mean duration of radiographic follow-up was 3.8 years (range, 2–5). Curve types according to the Lenke system were the following: 1CN (n = 20), 1C– (n = 3), 1C+ (n = 2), 2CN (n = 33), 2C– (n = 3), 3CN (n = 6), and 4CN (n = 11).

The average preoperative MT curve was 64° (range, 47°–79°). This decreased to 43° (range, 33°–66°) on side bending (flexibility, 33%; range, 5%–71%). The MT curve was corrected to an average 23° (range, 5°–34°) shortly after surgery and to 25° (range, 5°–35°) at the most recent follow-up (correction, 61%).

The average preoperative lumbar curve was 51° (range, 43°–63°). This decreased to 18° (range, 5°–35°) on side bending (flexibility, 65%; range, 40%–87%). The CL flexibility was not less than that of the MT curve in any patient. The CL curve had corrected to an average 25° (range, 9°–35°) shortly after surgery and to 23° (range, 9°–34°) at the most recent follow-up (correction, 55%).

The preoperative MT/CL ratio of Cobb magnitude was 1.3. Preoperative AVT-MT averaged 49 mm (range, 30–96 mm), and AVT-CL averaged 43 mm (range, 21–54 mm). The MT/CL ratio of AVT was 1.1. The preoperative AVR-MT Nash-Moe grade averaged 2.1 (range, 1.3–2.4), and AVR-CL averaged 2.1 for the lumbar curve (range, 1.7–2.5). The MT/CL ratio of AVR averaged 1.0 (Table 2).

For MTCL curves without thoracolumbar kyphosis, the fusions were to the stable vertebrae (T11 = 8, T12 = 31, and L1 = 35). For MTCL curves with thoracolumbar kyphosis, the fusions were to L1 so that the kyphosis could be corrected. In this series of patients, there were no patients with thoracolumbar kyphosis greater 20°. However, there were four patients with thoracolumbar kyphosis greater 10° (N = 4). All were successfully treated by STF to L1 with CBT and DVR. There was no evidence of increased kyphosis at the thoracolumbar junction (T12–L1) after surgery. The mean sagittal alignment at the thoracolumbar junction was 3° (range, –7° to 13°) before surgery and –3° (range, –7° to 2°) after surgery.

Lumbar Cobb improvement was evident in every patient who underwent selective MT fusion, and true correction of thoracic and lumbar AVT was consistent. The patients' improvement was based on whether there was any change in AVT-CL. AVT-CL improved to an average 22 mm immediately after surgery and to 20 mm (range, 8–28 mm) at the final follow-up, with a mean correction of 23 mm (range, 8–32 mm). Lumbar AVT improved in all patients, and in 61 of the 78 patients, it led to a change in the lumbar modifier grade (C to A in 28 patients and C to B in 33 patients).

TABLE 2. Radiographic Data for 78 Major Thoracic-Compensatory Lumbar Curves

Deformity	Preoperative	Ultimate Follow-up	Correction
MT Cobb (°)	64 (47 to 79)	25 (5 to 35)	61%*
CL Cobb (°)	51 (43 to 63)	23 (9 to 34)	55%*
Coronal balance (mm)	14 (−43 to 25)	12 (−42 to 21)	2
Sagittal balance (mm)	−2 (−21 to 19)	1 (−14 to 16)	3
AVT-MT (mm)	49 (30 to 96)	18 (7 to 26)	31*
AVT-CL (mm)	43 (21 to 54)	20 (8 to 28)	23*
AVR-MT (N-M grade)	2.1 (1.3 to 2.4)	1.8 (1.2 to 2.1)	0.3
AVR-CL (N-M grade)	2.1 (1.7 to 2.4)	1.9 (1.6 to 2.1)	0.2

Data are presented as the mean or mean (range) unless otherwise specified.
**Statistically significant change (P < 0.05).*
AVR indicates apical vertebral rotation; AVT, apical vertebral translation; CL, compensatory lumbar curve; MT, main thoracic curve; N-M, Nash-Moe.

AVT-MT improved to 18 mm at final follow-up, with a mean correction of 31 mm. Apical vertebral rotation-CL exhibited inconsistent spontaneous correction after surgery or at later follow-up. The average preoperative AVR-CL was 2.1 Nash-Moe grade. This decreased to 1.9 at the final follow-up, but there was no significant difference. The average AVR-MT improved from preoperation 2.1 Nash-Moe grade to 1.8 at the latest follow-up. However, the difference was not significant.

No significant change in the global sagittal and coronal balance was observed after surgery. The average global sagittal balance was −2 mm (range, −21 to 19 mm) before surgery and 1 mm (range, −14 to 16 mm) at the latest follow-up. The mean global coronal balance was 14 mm before surgery (range, −43 to 25 mm), and it did not change significantly after surgery (mean, 12 mm; range, −42 to 21 mm) (Tables 2). There are five patients with more than 20 mm deviation to the left side and one patient with more than 20 mm deviation to the right side before operation and four patients with more than 20 mm deviation to the left side and two patient with more than 20 mm deviation to the right side after operation. According to the Lenke's guidelines, the lumbar curve is structural if the residual lumbar curve's Cobb measurement on side bending is 25° or greater. In this study, it was found that all 6 Lenke 3C and 11 Lenke 4C curves, which met the three study criteria and which should not be treated by STF according to Lenke guideline, could be successfully treated with STF by using CBT and DVR. The average preoperative lumbar curve was 54° (range, 51°–62°), and it decreased to 31° (range, 25°–35°) on side bending (flexibility, 43%). The average postoperative lumbar curve was 27° (range, 14°–34°; correction, 50%). The results demonstrate that Lenke 3C or 4C curves with MT/CL ratios of Cobb magnitude and AVT greater than one, MT/CL ratio of flexibility less than one, and the Cobb magnitude of residual lumbar curve on side bending between 25° and 35° can be successfully treated with STF by using CBT and DVR (Figures 1 and 2).

According to Lenke guidelines, for Lenke 1C or 2C curves to be successfully treated by STF, the MT/CL ratio of Cobb

measurements, AVT, and AVR should be 1.2 or greater. In contrast, for Lenke 1C or 2C curves in this study, the MT/CL ratio of Cobb measurement and AVT greater than one were required for successful STF. Among the 78 MTCL curves, there were 32 Lenke 1C or 2C curves, which were not recommended for STF according to Lenke's guidelines. Among these, there were 28 Lenke 1C or 2C curves with the MT/CL ratio of Cobb measurement greater than 1.2 (mean, 1.05; range, 1.0–1.2). Twenty-six of the 32 Lenke 1C or 2C curves had an MT/CL ratio of AVT 1.2 or less. (mean, 1.1; range, 1.0–1.2). Twenty-one of the 32 Lenke 1C or 2C curves had an MT/CL ratio of AVR less than 1.2. (mean, 1.0 range, 0.8–1.2). All these curves, which should not be treated by STF according to Lenke's guideline, can be successfully treated by STF with CBT and DVR. The results demonstrated that Lenke 1C or 2C curves with equal magnitude of thoracic and lumbar curves and/or with equally deviated lumbar curves and/or with equal or more dominant lumbar rotation can be successfully treated with STF by using CBT and DVR.

DISCUSSION

Certain curve patterns leave little doubt about the ability to preserve lumbar motion. Those curves with only a thoracic deformity (King-Moe III, V and Lenke 1A, 2A) have long been treated with the distal level of fusion, generally a level or two proximal to the stable vertebra. This rarely results in a fusion distal to L2. On the contrary, there are curve patterns that routinely require fusion to L3 or L4. When the primary curve is in the lumbar or thoracolumbar region, lumbar fusion is unavoidable if surgical correction is undertaken. The debate about including the lumbar spine in the fusion has always focused on those curves with both a MT and a CL component.

Lumbar motion will be important for function during the patients' remaining decades of life. There is a reason to believe that distal degeneration will be less problematic if more motion segments remain below a fusion.⁸ Sparing the lumbar spine from fusion should be a goal whenever practical. Also, there is a reason to believe that lumbar degeneration will be

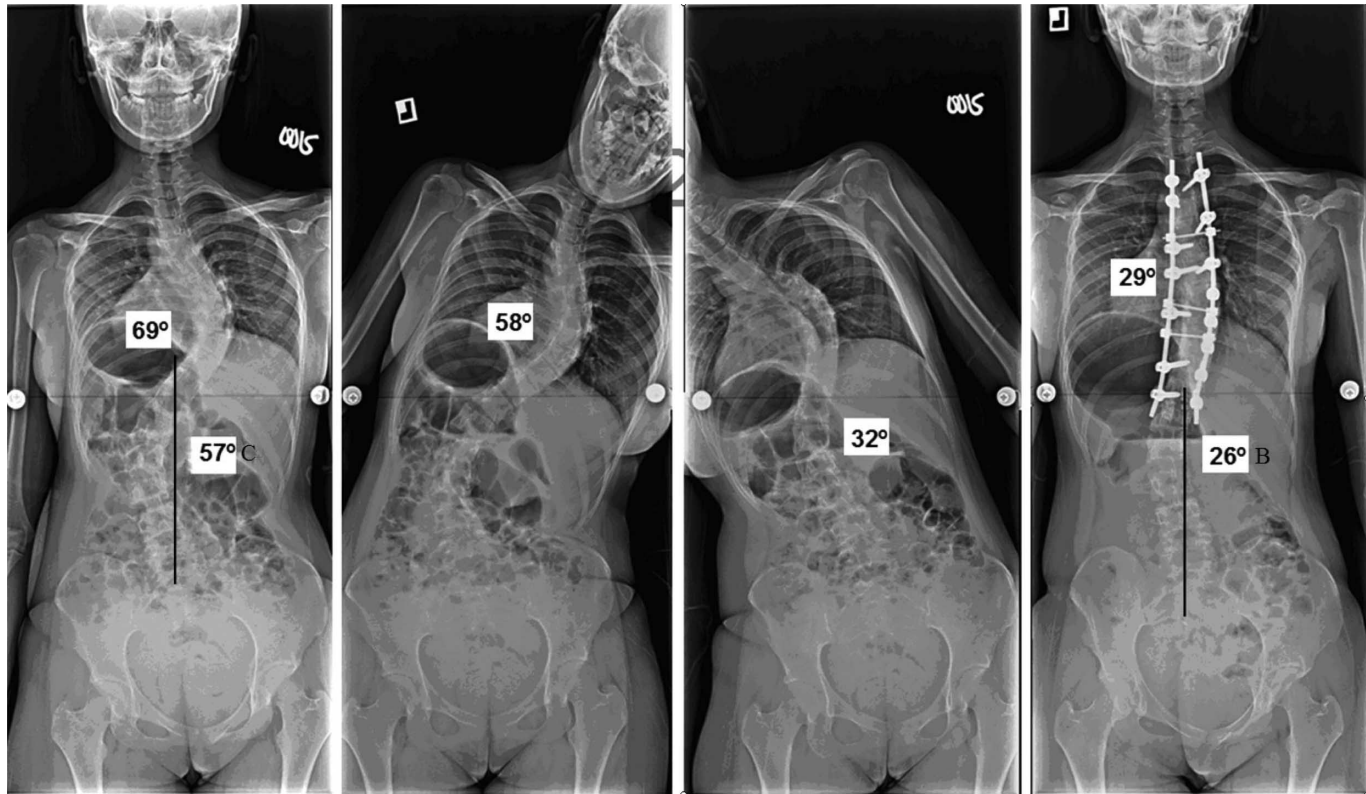


Figure 1. A Lenke 3C curve that met the three study criteria was successfully treated by selective thoracic fusion with cantilever bending and direct vertebral rotation.

less problematic if optimal spontaneous lumbar correction can be obtained. The goal of STF for MTCL curves should be not only to limit the number of fused lumbar segments but

also to optimize instrumented thoracic and spontaneous lumbar curve correction. Theoretically, this should minimize both transitional breakdown immediately below the fused region

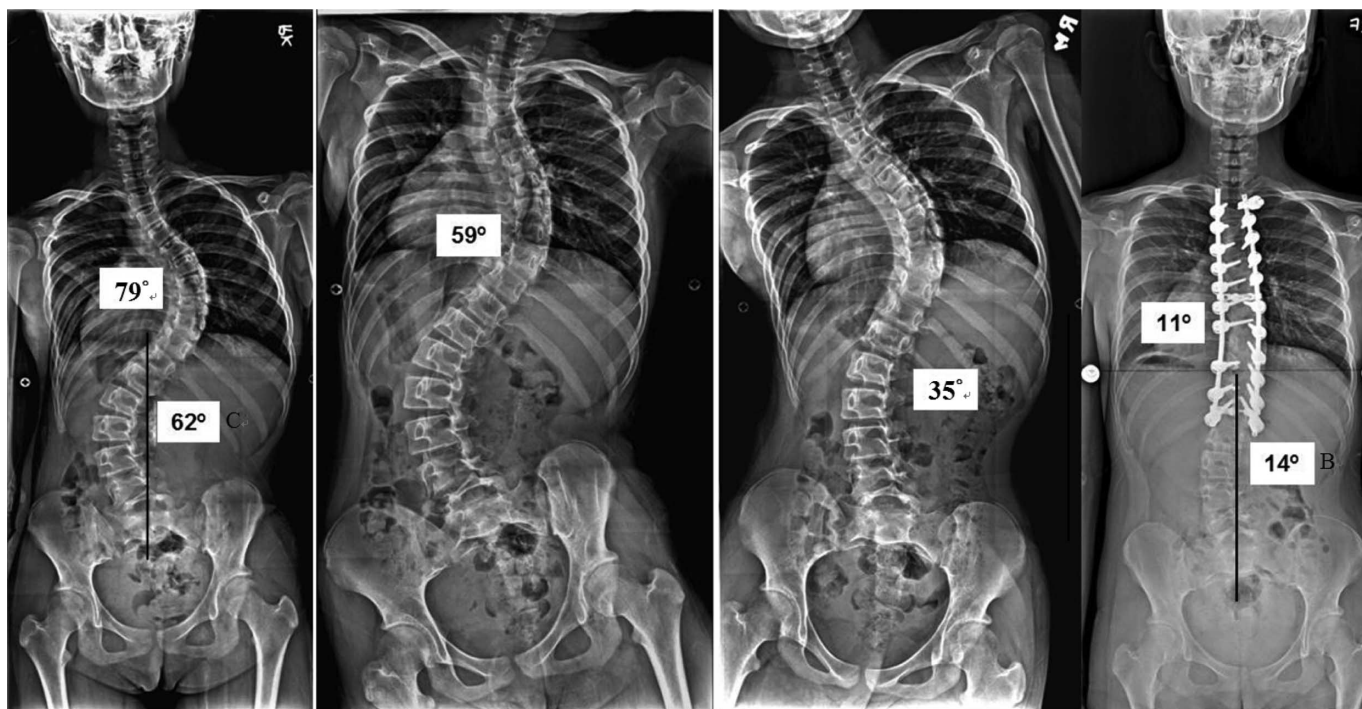


Figure 2. A Lenke 4C curve that met the three study criteria was successfully treated by selective thoracic fusion with cantilever bending and direct vertebral rotation.

and the rate of development of degenerative changes throughout the unfused lumbar spine.

King *et al*¹ in 1983, Lenke *et al*^{2,9} in 2001, and Qiu *et al*³ in 2003 described classification systems to help surgeons identify those curve types that are most amenable to STF. Comparing the three guidelines (Table 1) of MTCL curves for STF, we discovered that the fate of the lumbar spine is, to some degree, dictated by the nature of the scoliosis but is also dependent on the appended surgical technique.

Among the 78 MTCL curves determined as treatable with STF by using the study curve criteria, there were 14 Lenke 1C, 18 Lenke 2C, 6 Lenke 3C curves, and 11 Lenke 4C curves that were not recommended for STF according to Lenke curve criteria but could be successfully treated with STF with this technique. The results demonstrated that STF by using CBT and DVR can add more MTCL curves for STF than by following Lenke curve criteria. Compared with the Lenke series,⁵ this technique improved the quality of the instrumented thoracic correction from 36% to 61% and the spontaneous lumbar correction from 31% to 55%. True spontaneous correction of lumbar curve with significant improvement in AVT was consistent in all patients. The results demonstrated that CBT and DVR could not only broaden the curve criteria to include more MTCL curves to be treated with STF but also optimize instrumented thoracic and spontaneous lumbar correction.

Currently, relative axial rotation of the thoracic and lumbar region is one of the most important determinants in deciding whether to include the lumbar curve in the fusion. This is difficult to assess radiographically (Nash-Moe⁷ or Perdriolle methods) because of questionable accuracy.^{10,11} Efforts to include an absolute value or a grade for lumbar alignment in the axial plane as one of the structural criteria were found to be difficult to reproduce. Clinical evaluation of the patient during a forward bend seems more helpful than the radiographs in making this assessment. It is generally believed that a selective fusion is inappropriate if the lumbar rotational prominence is dominant compared to the thoracic region. A report by Thompson *et al*¹² discussed the potential for transmitting torque to the lumbar spine through derotation of the thoracic spine. The theoretical concern is that derotation potentially transmits forces to the lumbar spine, aggravating torsional deformity of the lumbar spine,^{1,12-15} and induces deformity in the coronal and sagittal planes, thereby reducing the lumbar curve's ability to compensate for thoracic curve correction. Thompson *et al*¹² recommended that derotation should be avoided in instrumentation of major thoracic curve. These recommendations reflect the ineffectiveness of current STF techniques in controlling the transmission of the forces used for the correction of thoracic curve.

[AQ4] In this study, 21 Lenke 1C or 2C curves with MT/CL ratio of AVR less than 1.2 and with equal or more dominant lumbar rotational prominence. All of these curves can be successfully and satisfactorily treated by STF with this technique. Postoperative radiography showed that AVR was either improved or unchanged but never became aggravated, and therefore, couple aggravation of the lumbar

curve or postoperative decompensation did not occur. We believe that the results demonstrate that forceful and direct rotation of the thoracic apical vertebra and low-end vertebrae of the thoracic curve in the opposite direction by DVR, reinforced with pressing the rib hump and twisting the pelvis in the opposite direction and locking the relative position on the convex rod, was an effective technique to prevent transmission of thoracic detorque to the lumbar curve and initiate detorque for the lumbar curve. That is the reason why we did not include relative axial rotation of the thoracic and lumbar region as a criterion for STF. We believe that this technique was the key procedure for successful STF and should be executed exactly.

We chose 35° as a cutoff point because this technique always can obtain spontaneous correction of lumbar curve better than or at least approximate to the magnitude of lumbar curve in side bending, and a residual lumbar curve of 35° is acceptable to us. We have no idea of the results of this technique for larger lumbar curves.

In this study for Lenke 1C or 2C curves with or without fulfilling the Lenke's ratio criteria, STF by this technique can be performed without any limitation during operation. We would bend the convex rod to a straight rod during correction. For IIIC or IVC curves with lumbar curve in side bending between 25° and 35°, we would not bend the convex rod to a straight rod but left a little curve to the rod (but still overcorrected the thoracic curve), because knowing the lumbar curve was not expect to accommodate as well as the lumbar curve of 1C or 2C MTCL curves with full correction of the thoracic curve. These details based on our experience must be [AQ5] notified to avoid misleading.

Thoracolumbar kyphosis before surgery may also lead a surgeon to perform a more distal fusion in patients who might otherwise have been candidates for selective fusion. According to Lenke classification, hyperkyphosis in the thoracolumbar region is a critical factor for determining selective or nonselective fusion. A Lenke classification criterion states that if the T10-L2 kyphosis measures greater than 20°, the thoracolumbar/lumbar region is considered "structural" and fusion is suggested across these levels. We did not include thoracolumbar kyphosis as a criterion for fusion of both curves, because it could easily be corrected or prevented by CBT.⁶ Global thoracic hyperkyphosis might also require correction by instrumentation distal to L2 or L3 in some cases. However, there were no such cases in this study. The sagittal plane deserves equal attention with the coronal plane, and the distal level of fusion must be appropriate for the deformity in both planes.

In the coronal plane, the CBT lifts up the convex lower thoracic spine and subsequently pull up the concavity of the upper lumbar curve, thereby translating it to the midline. However, no significant change in the coronal balance was observed after surgery. We realize that Cobb angles may be corrected quite impressively, but what the patients more preferably notice will be the balance of their trunks and shoulders. We did not evaluate this in this study, but we believe that this is a shortcoming of STF.

References

1. King HA, Moe JH, Bradford DS, et al. The selection of fusion levels in thoracic idiopathic scoliosis. *J Bone Joint Surg Am* 1983;65:1302-13.
2. Lenke LG, Betz RR, Harms J, et al. Adolescent idiopathic scoliosis: A new classification to determine extent of spinal arthrodesis. *J Bone Joint Surg Am* 2001;83-A:1169-81.
3. Qiu G, Zhang J, Wang Y, et al. A new operative classification of idiopathic scoliosis: A peking union medical college method. *Spine (Phila Pa 1976)* 2005;30:1419-26.
4. Yu B, Zhang JG, Qiu GX, et al. Posterior selective thoracic fusion in adolescent idiopathic scoliosis. *Chin Med Sci J* 2004;19:216-20.
5. Edwards CC II, Lenke LG, Peelle M, et al. Selective thoracic fusion for adolescent idiopathic scoliosis with C modifier lumbar curve: 2 to 16-year radiographic and clinical results. *Spine (Phila Pa 1976)* 2004;29:536-46.
6. Chang KW, Chang KI, Wu CM. Enhanced capacity for spontaneous correction of lumbar curve in the treatment of major thoracic-compensatory C modifier lumbar curve pattern in idiopathic scoliosis. *Spine (Phila Pa 1976)* 2007;32:3020-9.
7. Nash CL, Jr, Moe JH. A study of vertebral rotation. *J Bone Joint Surg Am* 1969;51:223-9.
8. Large DF, Doig WG, Dickens DR, et al. Surgical treatment of double major scoliosis. Improvement of the lumbar curve after fusion of the thoracic curve. *J Bone Joint Surg Br* 1991;73:121-4.
9. Lenke LG, Bridwell KH, Baldus C, et al. Preventing decompensation in King type II curves treated with Cotrel-Dubousset instrumentation: Strict guidelines for selective thoracic fusion. *Spine (Phila Pa 1976)* 1992;17(8) (suppl):S274-81.
10. Richards BS. Measurement error in assessment of vertebral rotation using the Perdriolle torsionmeter. *Spine (Phila Pa 1976)* 1992;17:513-7.
11. Ho EK, Upadhyay SS, Ferris L, et al. A comparative study of computed tomographic and plain radiographic methods to measure vertebral rotation in adolescent idiopathic scoliosis. *Spine (Phila Pa 1976)* 1992;17:771-4.
12. Thompson JP, Transfeldt EE, Bradford DS, et al. Decompensation after Cotrel-Dubousset instrumentation of idiopathic scoliosis. *Spine (Phila Pa 1976)* 1990;15:927-31.
13. Bridwell K, McAllister J, Betz R, et al. Coronal decompensation produced by Cotrel-Dubousset "derotation" maneuver for idiopathic right thoracic scoliosis. *Spine (Phila Pa 1976)* 1991;16:769-77.
14. Lenke LG, Bridwell KH, Baldus C, et al. Preventing decompensation in King type II curves treated with Cotrel-Dubousset instrumentation. Strict guidelines for selective fusion. *Spine (Phila Pa 1976)* 1992;17(8) (suppl):S274-81.
15. Von Lackum WH, Miller JP. Critical observations of the results in the operative treatment of scoliosis. *J Bone Joint Surg Am* 1949;31A:102-6.