

Correction Hinge in the Compromised Cord for Severe and Rigid Angular Kyphosis With Neurologic Deficits

Kao-Wha Chang, MD,*† Ching-Wei Cheng, PhD,‡ Hung-Chang Chen, MD,*
and Tsung-Chein Chen, MD*

Study Design.

Retrospective study.

Objective. To report the use of a reliable and safe technique for the surgical management of severe and rigid angular kyphotic deformities with neurologic deficits.

Summary of Background Data. Severe and rigid angular kyphotic deformity can result in difficult to treat neurologic deficits. Previously described techniques are an ordeal for both the patient and the surgeon and run the risk of damaging the compromised spinal cord because of stretch, compression, deformation, and direct intraoperative cord manipulation during the procedure.

Methods. Seventeen consecutive patients with neurologic deficits due to severe and rigid angular kyphotic deformity were treated with circumferential neurologic decompression and correction by one-shot *in situ* cantilever bending at the apex of the deformity with a fixed hinge in the compromised spinal cord. The procedure involved minimal manipulation, stretching, compression, and deformation of the vulnerable cord. Minimum follow-up after surgery was 2 years (range: 2.5–6.4 years). Mean Cobb angle of kyphotic deformity was 105.3° (range: 85°–121°). All patients exhibited neurologic deficits. There were 6, 7, and 4 patients classified as Frankel B, C, and D, respectively. Etiologic diagnoses were congenital kyphosis in 6 and postinfectious kyphosis in 11 patients.

Results. Mean operation time was 194 minutes and average blood loss was 1621 mL. All patients showed neurologic improvement. Two of the Frankel B patients improved to Frankel E and 2 each to Frankel D and C. Two of the Frankel C patients improved to Frankel D, whereas 5 improved to Frankel E. All Frankel D patients improved to Frankel E. Kyphotic deformity correction was 30% in the sagittal plane. Complications were minor.

Conclusion. Circumferential neurologic decompression and one-shot cantilever bending correction with a fixed hinge in the compromised cord is a safe and effective alternative for surgical treatment of severe and rigid angular kyphotic deformities with neurologic deficits.

Key words: cantilever bending, circumferential neurologic decompression, hinge of correction, severe angular kyphosis. **Spine 2009;34:1040–1045**

Surgical treatment of severe and rigid angular kyphotic deformities, particularly those with neurologic deficit are particularly risky. The “sick spinal cord” may experience mechanical stresses due to the angular kyphosis itself and intraoperative manipulations, which may result in further neurologic damage. These intraoperative manipulations include: distraction, compression, and translation as a result of deformity correction; hanging down, kinking, or dural buckling due to spinal shortening;¹ and direct manipulation of the spinal cord. A reliable and safe treatment requires thorough neurologic decompression and adequate correction of the deformity without further compromising the spinal cord.

Numerous reconstructive techniques for this spinal deformity using the anterior and posterior approach or the single posterior approach have been reported.^{2–6} All have involved manipulation and translation of the spine and as such expose the fragile cord to the risk of intraoperative manipulation. Here, we describe a technique involving thorough neurologic decompression and deformity correction through a single posterior approach with minimal intraoperative manipulation of the compromised spinal cord.

Materials and Methods

Seventeen consecutive patients with neurologic deficits due to severe and rigid angular kyphosis were treated with circumferential neurologic decompression and one-shot cantilever bending correction with a fixed hinge in the compromised cord during the period of 2000 to 2005. Clinical records and radiographic materials from all patients (11 male and 6 female) who were followed up for more than 2 years (range: 2.5–6.4 years) after surgery were retrospectively reviewed. The clinical records were reviewed for demographic data, etiology of lesion, Frankel grades of neurologic deficit, operation time, average blood loss, functional improvement, and complications. The radiographic material was reviewed for preoperative evidence and location of neurologic compression (CT-myelography), Cobb angles of deformity, deformity correction, and pre- and postoperative sagittal plane spinal balance and complications related to instrumentation and stabilization. Deformity was measured assessing standing anteroposterior and lateral “14 × 17” radiographs using Cobb method. For patients who could not stand because of neurologic deficits, sitting long cassette radiographs were used. Sagittal spinal balance was determined by measuring the horizontal dis-

From the *Taiwan Spine Center, Taiwan, Republic of China; †Department of Orthopaedic Surgery, Armed Forces Taichung General Hospital, Taiwan, Republic of China; and ‡Department of Bio-industrial Mechatronics Engineering, National Chung Hsing University, Taiwan, Republic of China.

Acknowledgment date: June 29, 2008. First revision date: October 6, 2008. Second revision date: November 11, 2008. Acceptance date: November 13, 2008.

The manuscript submitted does not contain information about medical device(s)/drug(s).

No funds were received in support of this work. No benefits in any form have been or will be received from a commercial party related directly or indirectly to the subject of this manuscript.

Address correspondence and reprint requests to Kao-Wha Chang, MD, National Chung Hsing University, Department of Bio-industrial Mechatronics Engineering, 250 Kou-Kuang Rd. Taichung 402, Taiwan, Republic of China; E-mail: kao-wha@803.org.tw

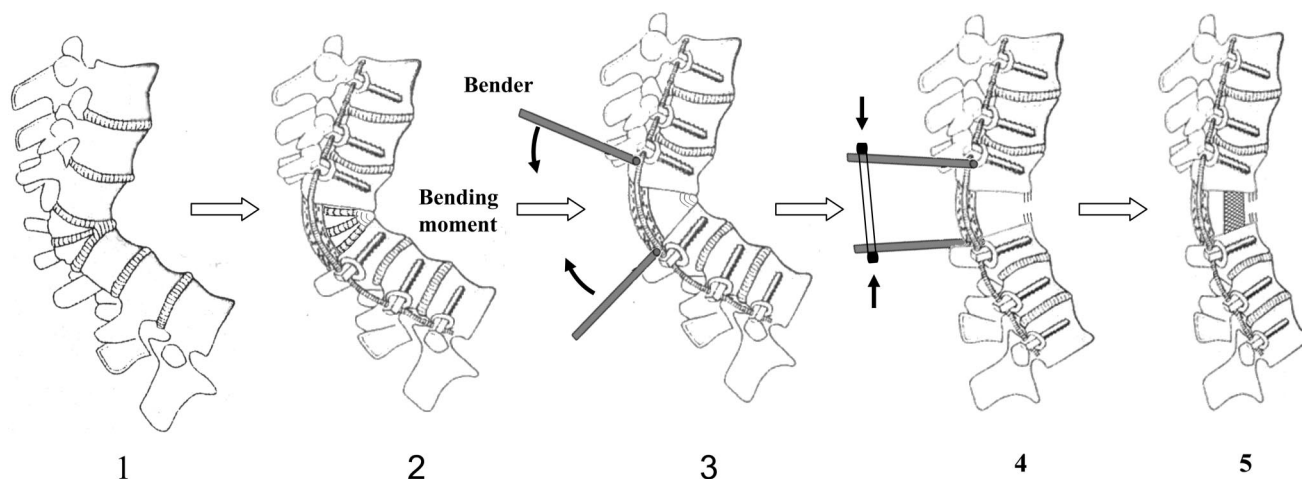


Figure 1. Correction hinge in the compromised cord to ensure stability of the compromised cord. (1) Severe angular kyphosis. (2) Laminectomy, pediclectomy, and situate rods on the same plane as the cord. (3) Complete circumferential decompression and connect benders to the rods. (4) Cantilever bending to correct kyphosis. (5) Insert mesh cage to provide anterior support and release the benders.

tance between C7 plumb line and the posterior superior S1 corner.

Etiologic diagnoses were congenital kyphosis in 6 and postinfectious kyphosis in 11 patients. Mean age at the time of surgery was 51.3 years (range: 31.0–63.1 years), whereas mean follow-up duration was 4.1 year.

Surgical Techniques

Patients were placed in a prone position. Somato-sensory-evoked potentials were monitored during surgery.

A straight posterior midline incision was made. Following a subperiosteal dissection, 3 to 5 vertebrae above and below the apex (this was dependent on bone quality) were exposed to the tips of the transverse process. Pedicle screws were inserted segmentally except for at the levels of circumferential neurologic decompression where at least 3 segments of fixation were made at either end of the decompression. Dissection was then carried out laterally, exposing the ribs corresponding to the levels of circumferential neurologic decompression. The location of neurologic compression was at the apex of the kyphotic deformity in all patients as determined by preoperative radiographic analysis. The transverse process and the corresponding ribs on both sides of the neurologic decompression were removed to expose the lateral wall of the pedicle. The meticulous subperiosteal dissection was deepened following the lateral wall of the vertebral body until a comfortable working space for neurologic decompression beneath the compromised cord was evident. Care was taken to avoid damaging segmental vessels during the exposure process. Segmental vessels injured during dissection were clamped, ligated, and cut under spinal cord monitoring to ensure that there were no changes in somato-sensory-evoked potentials. Though circumferential neurologic decompression was crucial for neurologic recovery. Total laminectomy and facetectomy were carried out at the apex to expose the compromised neural tissue. In thoracic vertebrae, the nerve roots were cut to facilitate thorough neurologic decompression. Nerve roots were kept intact in lumbar vertebrae.

Total pediclectomy was performed to expose the lateral portion of the compromised dural tube. Pedicle screws were then connected on both sides (by 2 rods contoured to the shape of the deformity) to facilitate rigid fixation. Due to the marked angular change in segments around the apex, the rods could be

situated nearly on the same coronal plane as the compromised cord. This was achieved by adjusting the protruding height of the screw heads at the levels immediately cephalad and caudad to the apex (the level of circumferential neurologic decompression) and properly precontouring the rods (Figure 1, n 2). A tunnel beneath the compromised cord was created by penetrating a blunt-end cage trail from 1 side of the apical vertebra to the other. The tunnel was enlarged and the portion of the apical vertebral body above the tunnel and adjacent to the anterior compromised dural tube (including the posterior vertebral wall) was removed using rongeurs, curette, and pituitary forceps. Because severe kyphosis was present, removal of these tissues through a tangential approach was not particular challenging and thus minimizing trauma to the spinal cord. At this stage, the compromised cord was circumferentially decompressed. After the completion of neurologic decompression, a final check was performed to ensure that the canal was clear of any residual compression at the resection margins. Cancellous bone within the portion of the apical vertebral body beneath the tunnel was removed by curette to the depth of the anterior vertebral cortex. The cortex was weakened at several points by penetration with a blunt-end cage trail to facilitate its fracture while applying cantilever bending for correction.

One pair of *in situ* benders was connected to each contoured rod at the level immediately cephalad and caudad to the apex (Figure 1, n 3). The *in situ* bender was the usual *in situ* bender with a U-shaped head that was at a right angle with the shaft of the bender. The rod was stably locked in the U-shaped head at the connection point by tightly grasping the rod with the 2 arms of the U-shaped head while the surgeon and an assistant held the free ends of each pair benders, and tilted each paired benders into lordosis by moving the ends close together simultaneously to obtain adequate correction. The position of the *in situ* benders was fixed by using wire to tie the free ends at the desired location (Figure 1, n 4). At this stage, the apical vertebral body anterior to the cord fractured and opened with the correction hinge in the compromised cord; the length of the rod between the connection points of the rod with the paired *in situ* bender and the length of the compromised cord were immovable, which could be proved by the following biomechanical analysis.

Biomechanical Analysis

The material code of the selected rod (Diapason system, Stryker Ltd, France) was Ti-6AL-4V ELI, which has ultimate strength $\sigma_u = 989 \times 10^6 \text{ N/m}^2$, yield strength $\sigma_y = 867 \times \text{N/m}^2$, and elastic modulus $E = 110 \times 10^9 \text{ N/m}^2$. The axial deformation of the rod can be expressed as follows:

$$\delta = \frac{PL}{AE}$$

Where δ is the change in length of the rod of original length L .

P is the axial force in the rod.

A is the cross-sectional area of the rod.

E is the elastic modulus of the material.

For the crucial condition, assuming that $P = 1000 \text{ N}$, $A = \pi(5 \times 10^{-3})^2 \text{ m}^2$ and $L = 0.15 \text{ m}$, the corresponding elongation or deformation of the rod is equal to $1.74 \times 10^{-2} \text{ mm}$. As a result, the deformation of the rod because of axial loading can be ignored. To be most effective, the rods are located on the same coronal plane and parallel to the compromised cord so that the load can be considered as a pure bending moment. This ensures that deformation of the rod is the same as that of the compromised cord.

After fracturing the apical vertebral body (status of 3-column release) during correction by cantilever bending, the bending force was slowly increased. If resistance was felt, which meant great vessels were in tension, correction should be stopped and fixed. The force put on the bend and correction obtained by this way would be safe to patients. However, great vessels always exhibited sufficient elasticity to allow stretching and obtaining adequate correction. No resistance was felt in any of these patients during correction.

A wake-up test was performed after correction. The height of the anterior interbody gap was measured. A titanium mesh filled with bone chip was inserted into the anterior gap and an autogenous iliac bone chip was placed around the titanium mesh. The mesh cage was inserted from the lateral side to fit on the cephalad and caudal bone base. Properly positioning the mesh cage was ensured by direct vision and intraoperative fluoroscopy. Ample space between the cage and the cord was assured before releasing the benders and locking the cage in place. (Figure 1, n 5). Two transverse links were connected to the rods at the cephalad and caudal levels to the level of neurologic decompression (Figure 2).

Posterior fusion was performed at all instrumented levels. Posterior bridging at the thoracic level was performed *via* bone grafting over the resection gap. Following this the wound was irrigated, closed, suction drains inserted at the decompression site and the surgical wound was closed in layers. Patients were fitted with custom-made plastic thoracolumbosacral orthoses and were allowed out of bed 72 hours after surgery. Orthoses were worn for 6 months.

Results

The mean operation time was 194 minutes (range: 168–241 minutes) and average blood loss was 1621 mL (range: 1151–2608 mL).

All patients exhibited radiographic evidence of neural compression at the apex on preoperative CT-myelography (Figures 2C, D). Neurologic deficits were categorized according to Frankel grade. There were 6, 7, and 4 patients with Frankel grade B, C, and D, respec-

tively. Following surgery, 2 of the 6 Frankel B patients improved to Frankel C, 2 improved to Frankel D, and 2 improved to Frankel E. Of the 7 Frankel C patients, 2 improved to Frankel D and 5 improved to Frankel E. All Frankel D patients improved to Frankel E (Table 1).

The apex was located at thoracic level (cephalad to T11) in 6 patients, at the thoracolumbar level (between T12 and L1) in 10 patients and at the lumbar level (caudal to L1) in 1 patient. The mean preoperative Cobb angle of kyphotic deformity was 105.3° (range: 85° – 121°). This was corrected to 68.3° (range: 60° – 78°) immediately after surgery and to 73.5° (range: 65° – 87°) at final follow-up. Mean correction was 30%. Preoperative sagittal imbalance was 6.7 cm (range: 3.1–10.8 cm). Postoperative sagittal balance improved to 4.8 cm (range: 1–7.3 cm) immediately after operation and to 5.1 cm (range: 1.3–7.5 cm) at final follow-up (Table 1).

Information on coronal plane curvature was available for all patients. There were 8 patients who exhibited scoliotic curves with a mean curve of 15.8° (range: 10° – 23°).

There were no cases of implant failure, cage dislodgement, or neurovascular complications. One case of postoperative infection was treated by debridement drainage and antibiotic treatment without any adverse effect on final outcome. Medical complications were relatively minor and all were resolved. Two cases of postoperative pneumonia were managed with respiratory therapy and antibiotics. The most common complication was catheter-related urinary tract infection (8 cases) and all were resolved with antibiotic treatment.

Discussion

Severe angular kyphosis creates a biomechanical environment promoting progression. The kyphotic deformity anteriorly shifts an individual's center of gravity, resulting in more flexion bending moments around the apex of the kyphosis, which in turn promotes further increases in kyphotic angulation. With increased deformity comes pain. Furthermore, the spinal cord is stretched over the internal kyphosis resulting in the development of, or increased neurologic deficit. If left untreated, congenital kyphosis or postinfectious kyphosis can lead to severe and rigid angular deformity and occasionally result in symptoms of compressive myelopathy.

The neurologic deficits associated with angular kyphosis may be subtle and difficult to elicit. The compromised spinal cord may only become apparent intraoperatively or after surgery when overt neurologic deficits develop.⁷ Treatment of severe and rigid angular kyphotic deformities with neurologic deficits are particularly challenging. The spinal cord is at risk from mechanical stresses placed on it due to the angular deformity itself and intraoperative manipulations. Therefore, surgical treatment should consist of neurologic decompression combined with adequate restoration of alignment to obtain anterior support and fusion without risking the vulnerable compromised cord.

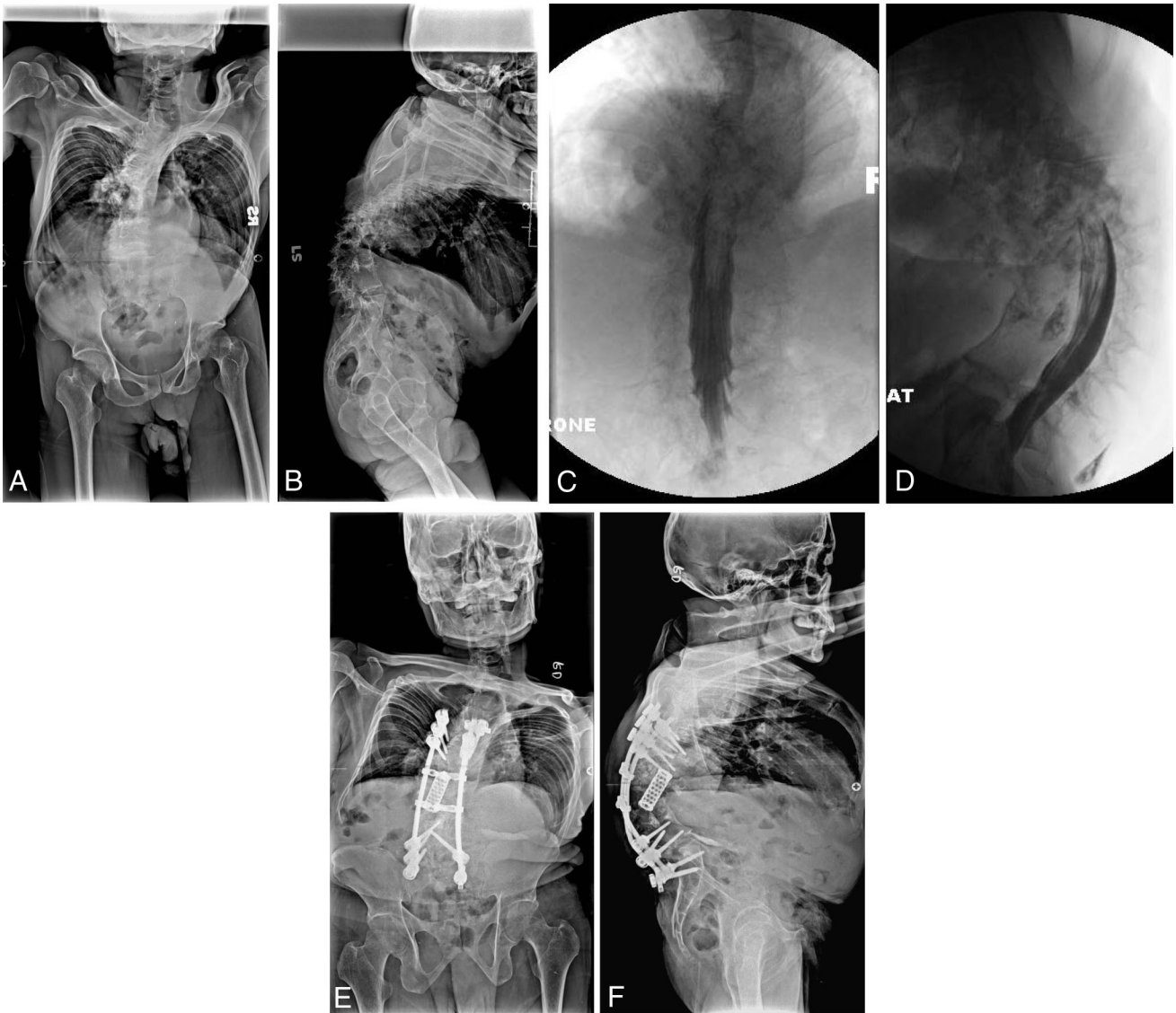

Figure 2. A 52-year-old man with Frankel B neurologic deficits due to postinfectious angular kyphosis. **A, B**, Preoperative lateral radiograph showed 107° angular kyphosis. **C, D**, Preoperative myelography revealed cord compromised at the apex. **E, F**, Postoperative radiographs taken 3.1 year after surgery revealed deformity correction to 68°. Neurologic deficits improved to Frankel E.

Surgical techniques for the reliable and safe correction of severe and rigid angular kyphosis with neurologic deficits are yet to be established. Leatherman and Dickson² described a technique for vertebral body resection using a 2-stage, combination anterior and posterior approach. Although Kawahara *et al*³ introduced “closing-opening wedge osteotomy,” Shimode *et al*⁴ described “spinal wedge osteotomy,” and Suk *et al*⁵ described “posterior vertebral column resection.” Further to this, Sar and Eralp⁶ described a technique for resection of posterior spinal elements and vertebral body and correction of the deformity using a 3-stage combination anterior and posterior approach. All the aforementioned surgical techniques correct angular kyphosis by exposing the apex circumferentially, using the anterior and posterior approach or the single posterior approach and performance circumferential spinal osteotomy. The corrective procedures involve shortening, distraction, and translation of

spinal columns while monitoring the spinal cord to avoid spinal cord damage. However, such corrective procedures expose the fragile cord to the dangers of intraoperative manipulations. Postoperative complications reported include permanent spinal cord injuries and transient neurologic deficits.⁵

A key step in the establishment of surgical techniques for treating severe angular kyphosis with neurologic deficits is minimizing the risk of trauma to the vulnerable spinal cord. Hereafter, we discuss why the surgical technique described in this manuscript is safer, less intensive, and time consuming than previous procedures.

In the described procedure, decompression of the dura sac was achieved by a tangential and bilateral approach. Such an approach minimizes trauma to the spinal cord and allows for high quality neurologic decompression.

The center of correction is defined as the hinge around which the deformity is corrected. The positions of the

Table 1. Cases

Case	Age/Sex	Follow-up (yr)	Diagnosis	Apex	Cobb Angle (°)			Correction (%)	Sagittal Balance (cm)			Frankel Grade		Op. Time (min)	Blood Loss (mL)
					Preop	Impo	Final Follow-up		Preop	Postop	Final Follow-up	Preop	Postop		
1	51.1/M	6.4	Post TB	T11	106	71	75	29	9.1	7.3	7.5	C	E	217	2440
2	46.2/M	6.1	Post TB	T10	108	67	72	33	6.8	4.8	5.0	D	E	241	2608
3	31/M	5.8	Post TB	T12	113	73	76	33	9.8	7.2	7.4	C	E	214	2085
4	58.3/F	5.6	Congenital	T11	96	64	69	28	5.1	3.7	3.7	C	E	221	2130
5	63.1/M	5.1	Post TB	T12	121	78	87	28	10.8	7.3	7.5	C	D	173	1350
6	61.3/M	4.5	Congenital	L1	89	63	67	25	3.3	1.9	2.2	B	C	186	1215
7	42.4/F	4.5	Post TB	T9	107	74	81	24	7.2	5.3	5.8	C	E	177	1235
8	46.6/M	4.0	Post TB	L1	110	71	74	33	8.6	6.8	7.4	C	D	181	1325
9	57.1/F	3.6	Congenital	T12	92	62	67	27	3.6	2.4	2.8	B	D	201	1690
10	48.7/M	3.5	Post TB	L2	116	78	83	28	8.1	5.9	6.1	C	E	210	1915
11	52.1/M	3.1	Post TB	T12	107	63	68	36	7.0	5.6	5.8	B	E	179	1535
12	61.4/M	3.1	Congenital	T11	85	60	65	24	3.1	1	1.3	D	E	190	1360
13	60.1/F	3.0	Congenital	T12	93	64	67	28	3.7	2.4	2.8	D	E	183	1320
14	51.1/F	2.9	Post TB	T12	114	75	78	32	6.7	4.7	4.9	B	C	203	1715
15	51.3/M	2.8	Post TB	T10	118	67	81	31	8.3	6.8	7.0	D	E	188	1300
16	54.2/F	2.7	Congenital	T12	98	61	65	34	4.0	2.8	3.3	B	D	168	1151
17	36.3/M	2.5	Post TB	L1	117	70	74	37	8.6	5.8	6.7	B	E	170	1180
Average	51.3	4.1			105.3	68.3	73.5	30	6.7	4.8	5.1			194	1621

TB indicates tuberculosis; Preop, preoperative; Impo, immediate postoperative; Corr, correction; Op, operation.

centers of correction in previous techniques were not fixed and constant. The hinge was located either anteriorly or moved posteriorly to the spinal cord during the corrective procedures. The length of the vulnerable cord changes if the center of correction is not in the spinal cord and thus leads to risk of stretch, compression, and deformation. Using the current technique, it was possible to situate the rods very nearly on the same coronal plane and parallel to the compromised cord. The connection points between the paired *in situ* benders and the rods were at the levels immediately cephalad and caudad to the compromised cord. Use of the *in situ* cantilever bending technique to correct angular kyphosis allows for fixation of the length between the connection points of each rod and thus also fixation of the length of the vulnerable spinal cord. This protects the spinal cord from the dangers of stretch, compression, and deformation during the procedure of correction.

The spinal column is completely divided and unstable after performance circumferential spinal osteotomy. The compromised cord might be further damaged by any corrective manipulation of the unstable vertebral columns. The previous techniques involved exchanging the temporary rods repeatedly.^{3,5,6} In contrast, the current technique provides rigid fixation before vertebral body osteotomy and for the duration of surgery, thereby facilitating the maintenance of spinal stability throughout the corrective procedure and minimizing the risk of intraoperative mishaps due to instability.

With the current technique, there was only a single manipulation of the spinal column *via* one-shot cantilever bending during the corrective procedure. This is in contrast to previous methods, where repeated manipulation of the spinal column involved additional compression and shortening of the vertebral column and ex-

changing the precontoured rods as necessary for the stage of correction. Multiple manipulations of the vertebral column during correction increase the risk of mishaps and the duration of surgery.

A further advantage of our technique is that exposure of the apex of the deformity was less than in those previously described. In previous reports, exposing the entire circumference of the apical vertebra in the same surgical field was essential for safe and reliable execution of subsequent steps. With the current surgical technique, a smaller area was exposed to facilitate tunneling beneath the compromised cord for circumferential neurologic decompression. Circumferential exposure of the apical vertebral body to remove the anterior cortex is not required because the application of cantilever bending would fracture the residual weakened cortical shell.⁸ The smaller exposure results in decreased ligature of segmental vessels, fewer impediments to intraparenchymal or extraparenchymal spinal cord blood flow, decreased risk to the compromised cord, and decreased surgery duration.

In these severe angular kyphosis, a fixed lordotic segment cephalad and caudad to the kyphotic segment hinders complete reconstruction of sagittal balance and alignment. The current technique shifts the patient's center of the gravity posteriorly, sufficiently restores sagittal balance, and locates anterior titanium mesh to provide stable anterior support and fusion. Complete correction of kyphotic deformity was not the goal of the technique described.

The majority of patients in this study exhibited marked neurologic improvement. In several cases where spinal cord atrophy was apparent, even high-quality decompression did not lead to neurologic recovery (2 patients with preoperative Frankel B neurologic level improved to Frankel C neurologic level). However, further deterioration can be prevented in such patients. Scoliosis

was noted in 8 patients (47%) for whom these data were available. The curves were of mild to moderate magnitude (10°–23°) and would not in themselves require surgical treatment.

Severe angular kyphosis has 2 characteristics: steep angular change over segments around the apex and deformity 1 dimensionality. Only corrective forces in sagittal plane are necessary for correction. These 2 unique characteristics of deformity allow the rod to be situated on the same coronal plane as the compromised cord is located and to act as the hinge for sagittal correction by one-shot *in situ* cantilever bending. This procedure minimizes risk to the spinal cord of stretch, compression, deformation, and repeated manipulation of unstable vertebral columns. The result of our retrospective study confirmed our presumptions. No neurologic deterioration occurred and all patients exhibited neurologic improvement. The procedure described resulted in kyphosis correction of 30% and restoration of sufficient sagittal balance to maintain stable anterior support and fusion.

■ Key Points

- This is the first report of a technique with a fixed hinge in the compromised cord for the treatment of severe and rigid angular kyphosis with neurologic deficits.

- All patients exhibited neurologic improvement and marked kyphotic deformity correction in the absence of significant complications.
- The technique described is an effective, safe, and less time-consuming alternative for treatment of severe and rigid angular kyphosis with neurologic deficits.

References

1. Kawaham H, Tomita K. Influence of acute shortening on the spinal cord: an experimental study. *Spine* 2005;30:6130–20.
2. Leatherman KD, Dickson RA. Two-staged corrective surgery for congenital deformities of the spine. *J Bone Joint Surg Br* 1979;61:324–8.
3. Kawahara N, Tomita K, Baba H, et al. Closing-opening wedge osteotomy to correct angular kyphotic deformity by a single posterior approach. *Spine* 2001;26:391–401.
4. Shimode M, Kojima T, Sowa K. Spinal wedge osteotomy by a single posterior approach for correction of severe and rigid kyphosis or kyphoscoliosis. *Spine* 2002;27:2260–7.
5. Suk S, Kim JH, Kim WJ, et al. Posterior vertebral column resection for severe spinal deformities. *Spine* 2002;27:2374–82.
6. Sar C, Eralp L. Three-stage surgery in the management of severe rigid angular kyphosis. *Eur Spine J* 2002;11:107–14.
7. Macagno AE, O'Brien MF. Thoracic and thoracolumbar kyphosis in adult. *Spine* 2006;31:S161–70.
8. Chang KW, Chen HC, Chang KI, et al. Closing-opening wedge osteotomy for the treatment of sagittal imbalance. *Spine* 2008;33:1470–7.